Perforating Diseases 96

Ronald P. Rapini

Synonyms: ■ Hyperkeratosis follicularis et parafollicularis in cutem penetrans: Kyrle disease ■ Acquired perforating dermatosis: acquired reactive perforating collagenosis, acquired reactive perforating dermatosis, perforating disorder of uremia

Key features

- Group of disorders with transepidermal elimination of collagen, elastic tissue, or necrotic dermal connective tissue
- Papules or nodules with keratotic plugs
- Elastosis perforans serpiginosa is associated with genetic diseases or penicillamine administration and involves elastic tissue; lesions are typically annular and most commonly occur in flexural sites, in particular the neck
- Reactive perforating collagenosis occurs after minor trauma, involves collagen, and often involves the upper extremities
- Acquired perforating dermatosis is almost always associated with diabetes mellitus and/or the pruritus of chronic kidney disease (stages 4–5); it favors the lower extremities of adults
- Broadband or narrowband UVB phototherapy appears to be the most effective treatment for acquired perforating dermatosis

INTRODUCTION

The perforating diseases are a group of papulonodular skin disorders characterized by keratotic plugs or crusts in which dermal connective tissue "perforates" or is eliminated through the epidermis (Table 96.1). There are two prototypic perforating diseases, both of which can be inherited. *Reactive perforating collagenosis* (RPC) is associated with transepidermal elimination of primarily collagen fibers[1], whereas in *elastosis perforans serpiginosa* (EPS), primarily elastic fibers are extruded through the epidermis. The third major perforating disease is *acquired perforating dermatosis*, which usually develops during adulthood in association with diabetes mellitus and/or the pruritus of chronic kidney disease (stages 4–5)[2]. Many textbooks traditionally list "perforating folliculitis" as the fourth perforating disease[3], but, in the opinion of the author, this seems unjustified. It does not appear to be a specific entity, since perforation or rupture of follicles occurs in a wide variety of diseases classified as folliculitis, regardless of whether the pathogenesis involves bacteria, fungi, *Demodex* mites, drugs, physical trauma, or other mechanisms.

Some authorities have expanded the concept of the preceding so-called "primary" perforating diseases to include a variety of unrelated "secondary" perforating disorders in which transepidermal elimination of a substance occurs as a secondary component of a primary dermatosis (Table 96.2). As in most of the preceding perforating disorders, the epidermis often becomes hyperplastic, eventually surrounds the material to be extruded, and subsequently causes the material's elimination via normal keratinocyte maturation. Some of these disorders are discussed elsewhere in this text and involve perforation of endogenous substances, exogenous foreign material, infectious organisms, granulomas, and even neoplastic cells[4].

HISTORY

In 1916, Kyrle reported a diabetic woman with generalized hyperkeratotic nodules, which he called "hyperkeratosis follicularis et parafollicularis in cutem penetrans". Lutz first described EPS as "keratosis follicularis serpiginosa" in 1953, and, in 1955, Miescher described the histologic findings, naming it "elastoma intrapapillare perforans verruciforme". Mehregan, Schwartz, and Livingood reported the first child with RPC in 1967. A year later, Mehregan and Coskey expanded the concept of perforating disease to include perforating folliculitis in their article.

EPIDEMIOLOGY

The perforating diseases are found worldwide, without any clear racial predilection. The very rare childhood-onset form of RPC is commonly familial, and childhood-onset EPS is occasionally familial. Although the exact inheritance pattern for both is still uncertain, isolated inherited EPS may have an autosomal dominant pattern. EPS affects men more often than women, with a ratio of ~4:1, whereas the sex distribution is nearly equal in RPC and acquired perforating dermatosis. Perforating folliculitis is said to be more common in women. In patients receiving maintenance hemodialysis, acquired perforating dermatosis is observed in an estimated 4.5% to 11% of patients[5]. Acquired perforating dermatosis is more commonly encountered than the inherited perforating disorders.

PATHOGENESIS

The precise pathogenesis underlying the perforating disorders is unknown. As it is unlikely that dermal connective tissue or hair shafts actively perforate into the epithelium, some have argued that "transepidermal elimination" is a more accurate term. The term "perforating" is embedded in the dermatologic lexicon, however, and is easier to say. Epithelium becomes hyperplastic and eventually surrounds the abnormal connective tissue, just as it appears to do with wood splinters or other foreign bodies. In acquired perforating dermatosis, pruritus probably leads to chronic scratching, which results in epithelial hyperplasia, as in prurigo nodularis. Indeed, prurigo nodules are often admixed with classic perforating lesions. The possibility has been raised that enlargement of a hyperkeratotic plug could lead to penetration through the base of the hyperplastic epidermis, i.e. the perforation is caused by the plug above rather than being due to the abnormal connective tissue below.

Primary perforating diseases may be due to either genetic or acquired abnormalities of collagen or elastic fibers. In EPS, as well as some cases of acquired perforating dermatosis in which perforation of elastic fibers is observed, enhanced expression of elastin receptors has been detected in the epidermis surrounding the elastic material[6]. It has been proposed that scratching exposes keratinocytes to *a*dvanced *g*lycation *e*nd product (AGE)-modified extracellular matrix proteins, in particular collagen types I and III. This would then lead to terminal differentiation of keratinocytes via the AGE receptor (CD36), followed by upward movement of keratinocytes along with glycated collagen[7]. Increased levels of AGEs have been detected in the skin of patients with acquired perforating dermatoses[8].

Plasma fibronectin levels are elevated in patients with diabetes mellitus and uremia, and fibronectin is also increased within the skin at sites of transepidermal elimination[9]. This may be significant, since fibronectin plays a role in epithelial cell signaling, locomotion, and differentiation. It binds to type IV collagen (the type found in basement membranes) and to keratinocytes and may incite epithelial proliferation and perforation. In one study of RPC, the investigators demonstrated that the collagen being transepidermally eliminated was type IV collagen[10]. Increased expression of transforming growth factor-β_3 (TGF-β_3), matrix metalloproteinase-1 (MMP-1), and tissue inhibitor of metalloproteinase-1 (TIMP-1) has been observed in lesional skin of acquired RPC[11], but this enhanced expression may be a reflection of concurrent wound healing (see Ch. 141).

Downloaded for Anonymous User (n/a) at Egyptian Knowledge Bank from ClinicalKey.com by Elsevier on March 10, 2024. For personal use only. No other uses without permission. Copyright ©2024. Elsevier Inc. All rights reserved.

MAJOR PERFORATING DISEASES					
Disease	**Incidence**	**Time of onset**	**Most common location**	**Perforating substance**	**Associations**
Familial reactive perforating collagenosis (RPC)	Very rare	Childhood	Arms, hands, sites of trauma	Collagen	None
Elastosis perforans serpiginosa (EPS)	Rare, M > F	Childhood, early adulthood; variable with penicillamine-induced EPS	Neck, face, arms, other flexural areas	Elastic tissue	Genetic diseases (see Fig. 96.13), penicillamine
Perforating folliculitis	Common	Early adulthood	Trunk, extremities	Necrotic material	May simply be ordinary folliculitis with follicular rupture, i.e. not a specific entity
Acquired perforating dermatosis, includes acquired RPC, Kyrle disease*, and rarely, acquired EPS	Common (10% of dialysis patients)	Adulthood	Legs or generalized	Necrotic material, collagen, or uncommonly, elastic tissue	Diabetes, chronic kidney disease (stages 4–5), pruritus, rarely liver disease; may be end stage of perforating folliculitis
Perforating calcific elastosis	Very rare, more common in Black women	Adulthood	Abdomen, periumbilical	Calcified elastic tissue	Multiparity, weight gain, obesity, hypertension

*In the opinion of some authors.

Table 96.1 Major perforating diseases. F, female; M, male.

SECONDARY PERFORATING DISEASES
Endogenous substances
Chondrodermatitis nodularis helicis Hematomas Perforating pseudoxanthoma elasticum Perforating calcinosis Osteoma cutis Gout (urate crystals) Papular mucinosis (mucin)
Granulomas
Perforating granuloma annulare (see Fig. 93.10) Necrobiosis lipoidica Sarcoidosis Rheumatoid nodule
Exogenous foreign material
Silica Wood splinters Tattoo Sutures Injectable soft tissue fillers
Infectious diseases
Chromoblastomycosis Leprosy Schistosomiasis
Tumor cells (more common examples)*
Melanoma Spitz nevus Pilomatricoma
*May be a nonspecific finding in a range of benign and malignant tumors due to "perforation" of the epidermis by complexes of neoplastic cells.

Table 96.2 Secondary perforating diseases. For a more extensive list, see reference 4.

Other proposed pathomechanisms include abnormal vitamin A or D metabolism, enzyme release from neutrophils[12], and microangiopathy related to diabetes. Deposition of uric acid, hydroxyapatite, or silicon[13] has also been implicated in the pathogenesis of perforating disorders.

CLINICAL FEATURES

Reactive Perforating Collagenosis

Familial RPC is a rare disorder that begins during childhood[1,14]. After superficial trauma, patients develop keratotic papules that reach a size of 5–8 mm over the following 3–4 weeks. The Koebner phenomenon may occur, in which injury to the skin results in the formation of new lesions, often in a linear distribution. Koebnerization is more commonly observed with RPC than with the other perforating disorders, but it has been reported with all of them. Arms and hands are the most common sites of involvement in RPC (Fig. 96.1). The papules tend to spontaneously resolve over 6–10 weeks. Verrucous perforating collagenoma (*collagenome perforant verruciformé*) is a very rare non-familial variant of RPC in which severe trauma to the skin results in verrucous papules with transepidermal elimination of collagen[15]. Acquired RPC that begins in adulthood usually occurs in association with diabetes mellitus and/or chronic kidney disease (stages 4–5), and these cases are best classified as acquired perforating dermatosis, even though the histopathology is identical to the inherited form of RPC.

Fig. 96.1 Reactive perforating collagenosis of the arm. Several erythematous papules with a central scale-crust core. *Courtesy Lorenzo Cerroni, MD.*

Elastosis Perforans Serpiginosa

EPS is a rare disorder whose onset is during childhood or early adulthood. About 40% of cases occur in association with other genetic disorders, including Down syndrome, Ehlers–Danlos syndrome, osteogenesis imperfecta, Marfan syndrome (Fig. 96.2), pseudoxanthoma elasticum (PXE), Rothmund–Thomson syndrome, and acrogeria. In a survey of pediatric dermatologists, the majority performed a detailed history and careful physical examination but did not embark upon an extensive search for these genetic disorders in an otherwise healthy child or adolescent with EPS[16].

Downloaded for Anonymous User (n/a) at Egyptian Knowledge Bank from ClinicalKey.com by Elsevier on March 10, 2024. For personal use only. No other uses without permission. Copyright ©2024. Elsevier Inc. All rights reserved.

Fig. 96.2 Elastosis perforans serpiginosa in the setting of Marfan syndrome. Annular papules and plaques developed on the ear.

Fig. 96.3 Elastosis perforans serpiginosa. Papules arranged in an annular configuration on the neck.

Fig. 96.4 Penicillamine-induced elastosis perforans serpiginosa. A Multiple annular plaques favoring the antecubital fossae. **B** Closer view with foci of hyperkeratosis at sites of transepidermal elimination.

Very rarely, EPS has been associated with chronic kidney disease (more rarely encountered than the acquired form of RPC) and may overlap with acquired perforating dermatosis. EPS has also been reported following long-term use of penicillamine, usually for 10 or more years. This drug is known to disrupt desmosine cross-links within elastin (see Ch. 97)[17]. Because penicillamine is used to treat Wilson disease, the possibility that abnormal copper metabolism plays a pathogenic role in EPS has been raised. However, EPS has also been observed in patients with cystinuria or rheumatoid arthritis who have received penicillamine.

Lesions of EPS are keratotic, 2- to 5-mm papules that tend to be arranged in a serpiginous or annular pattern, most commonly on the lateral neck (Fig. 96.3), but also on the face, arms (Fig. 96.4), or other flexural areas. The rings of papules may reach several centimeters in diameter. Most patients experience no symptoms or only mild pruritus. Like RPC, the lesions may spontaneously resolve, but in general tend to persist, often for several years.

Acquired Perforating Dermatosis and Kyrle Disease

Acquired perforating dermatosis has been used as a catch-all term for those perforating diseases that arise in adults, usually in association with diabetes mellitus and/or the pruritus of chronic kidney disease (stages 4–5)[2]. The majority of affected patients with established renal failure are receiving dialysis, and most of those with diabetes mellitus have associated nephropathy[18]. In individuals requiring dialysis, predictors for the development of acquired perforating dermatosis include diabetes mellitus, reduced circulating levels of intact parathyroid hormone, hypoalbuminemia, and elevated serum levels of high-sensitivity C-reactive protein[19]. This disorder can also occur in conjunction with other causes of pruritus, from insect bites and scabies to lymphoma and hepatobiliary diseases, including primary biliary cholangitis and hepatocellular carcinoma.

Acquired perforating dermatosis can arise from other forms of trauma (not just scratching), including within sites of healing herpes zoster. In addition, acquired perforating dermatosis and perforating folliculitis may develop following exposure to several classes of drugs including TNF inhibitors, epidermal growth factor receptor inhibitors (e.g. gefitinib, panitumumab) and other kinase inhibitors (e.g. nilotinib), dipeptidyl peptidase-4 inhibitors, antivirals (e.g. telaprevir, indinavir), sirolimus, and several monoclonal antibodies (e.g. natalizumab, bevacizumab). Of note, some of these medications more commonly induce an acneiform eruption with disrupted pilosebaceous units rather than a perforating dermatosis. While an association with hypothyroidism and hyperparathyroidism has been reported, most of these patients also had established risk factors (e.g. diabetes, nephropathy). Lastly, in a series of 22 patients with acquired perforating dermatosis, three were healthy and had no known associated illnesses and two were renal transplant recipients[18].

Acquired perforating dermatosis occurs most commonly on the legs (Fig. 96.5), but generalized or widely scattered papules and nodules can be seen (Figs. 96.6 & 96.7). Extensor surfaces are favored over flexures and the mucous membranes are spared. A clue to the diagnosis is the presence of a central keratotic core, which is sometimes physically removed by the patient. Occasionally, a giant variant is observed,

Downloaded for Anonymous User (n/a) at Egyptian Knowledge Bank from ClinicalKey.com by Elsevier on March 10, 2024. For personal use only. No other uses without permission. Copyright ©2024. Elsevier Inc. All rights reserved.

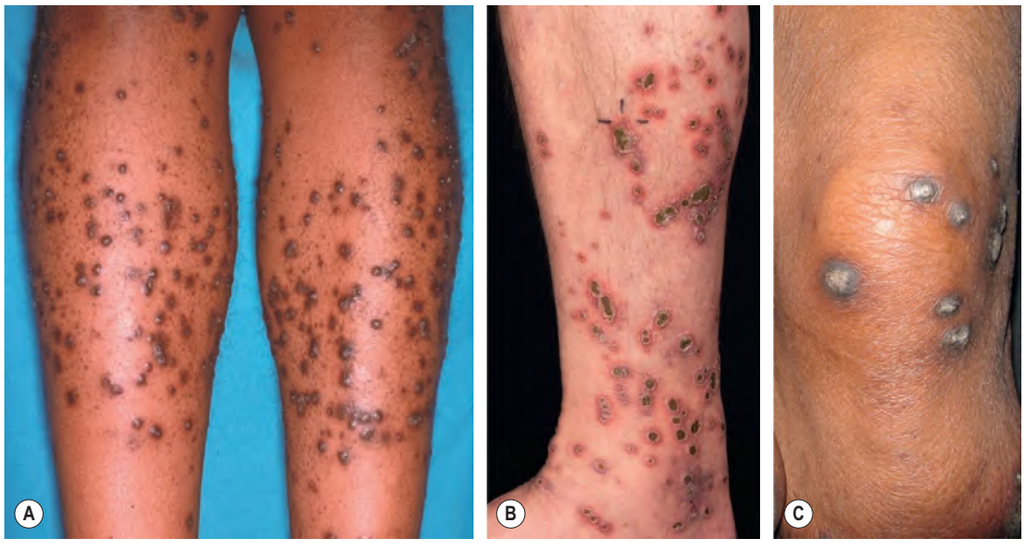

Fig. 96.5 Acquired perforating dermatosis. **A** Numerous hyperpigmented papules and nodules on the legs in a patient with both chronic kidney disease and diabetes mellitus. **B** The central portion of these lesions can be keratotic or composed of scale-crust. **C** Larger nodules in a patient receiving hemodialysis for end-stage kidney disease. *B, Courtesy Lorenzo Cerroni, MD; C, Courtesy Frank Samarin, MD.*

Fig. 96.6 Acquired perforating dermatosis. Erythematous papules with central keratotic cores in a patient with chronic kidney disease. Sometimes the latter are dislodged by the patient. *Courtesy Lorenzo Cerroni, MD.*

Fig. 96.8 Perforating calcific elastosis. When a biopsy was performed from the elevated edge of this supraumbilical plaque in a multiparous African-American woman, resistance was felt, as well as a grinding sound.

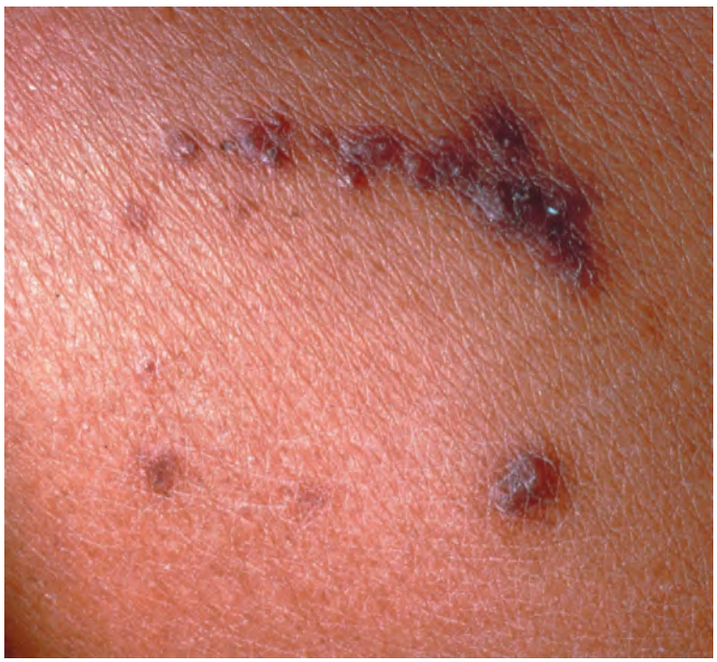

Fig. 96.7 Acquired perforating dermatosis. Note the linear arrangement of the keratotic papules (Koebner phenomenon).

where lesions may reach 2 cm in diameter. Rarely, secondary infections due to bacteria (e.g. *Staphylococcus aureus*), atypical mycobacteria (e.g. *Mycobacterium abscessus*), or fungi (e.g. *Mucor* spp.) have been reported.

Largely on the basis of histologic findings, patients with acquired perforating dermatosis have been variably designated in the literature as having RPC, EPS[2], perforating folliculitis[14], or perforating PXE. However, not only do the pathologic findings vary from lesion to lesion in the same patient, but there are often overlapping features. In addition, since some, but not necessarily all, of these lesions appear to be follicular, and since manipulation of the lesions by patients frequently alters the histologic changes, the term "acquired perforating dermatosis" was proposed to encompass all of these cases. Furthermore, since Kyrle had used the phrase "follicularis et parafollicularis" to emphasize that not all lesions were centered on hair follicles, the eponym Kyrle disease has been used synonymously with acquired perforating dermatosis by some authorities[2]. However, others do not consider Kyrle disease to be an entity or prefer to define it as merely representing the presence of end-stage, excoriated, prurigo nodules of folliculitis[2].

Perforating Calcific Elastosis

This disorder is characterized by plaques that favor the abdomen, especially the periumbilical region of middle-aged, obese, hypertensive, multiparous Black women (Fig. 96.8)[20]. Involvement of the breast in patients with chronic kidney disease has also been observed. The plaques may be verrucous or have keratotic papules at their periphery.

Downloaded for Anonymous User (n/a) at Egyptian Knowledge Bank from ClinicalKey.com by Elsevier on March 10, 2024. For personal use only. No other uses without permission. Copyright ©2024. Elsevier Inc. All rights reserved.

In histologic sections stained with H&E or von Kossa or Verhoeff–van Gieson stains, calcified elastic fibers (identical to those in PXE) are seen undergoing transepidermal elimination. However, affected patients do not manifest other clinical findings of PXE. Similar transepidermal elimination has been observed in patients with dermatitis who applied a commercially available calcium salt water normally used for making bean curd or were exposed to calcium chloride contained in ice-melting salt.

PATHOLOGY

In all the perforating diseases, there is a plug of crusting or hyperkeratosis, with variable parakeratosis, depending upon the stage of the lesion (Fig. 96.9A). As the plug enlarges, epithelial hyperplasia develops, sometimes with dyskeratosis of keratinocytes. At the site of perforation, the epithelial hyperplasia often resembles an elephant snout or crab claw. However, sections from multiple levels through the tissue may need to be examined to find the site of perforation. Some lesions may have aggregates of neutrophils within the dermis, while older lesions, particularly those of EPS, tend to have lymphocytes, macrophages, or multinucleated giant cells in the dermis at the site of perforation.

In RPC, basophilic (degenerative) collagen fibers, some of which are vertically oriented, are seen within the plug or within the epidermis (Figs. 96.9B & 96.10), whereas in EPS, elastic fibers are seen instead (in the same location; Fig. 96.11A). It is important to note, however,

Fig. 96.10 Reactive perforating collagenosis. Transepidermal elimination of red collagen fibers through the spinous layer and into the stratum corneum (Verhoeff–van Gieson stain).

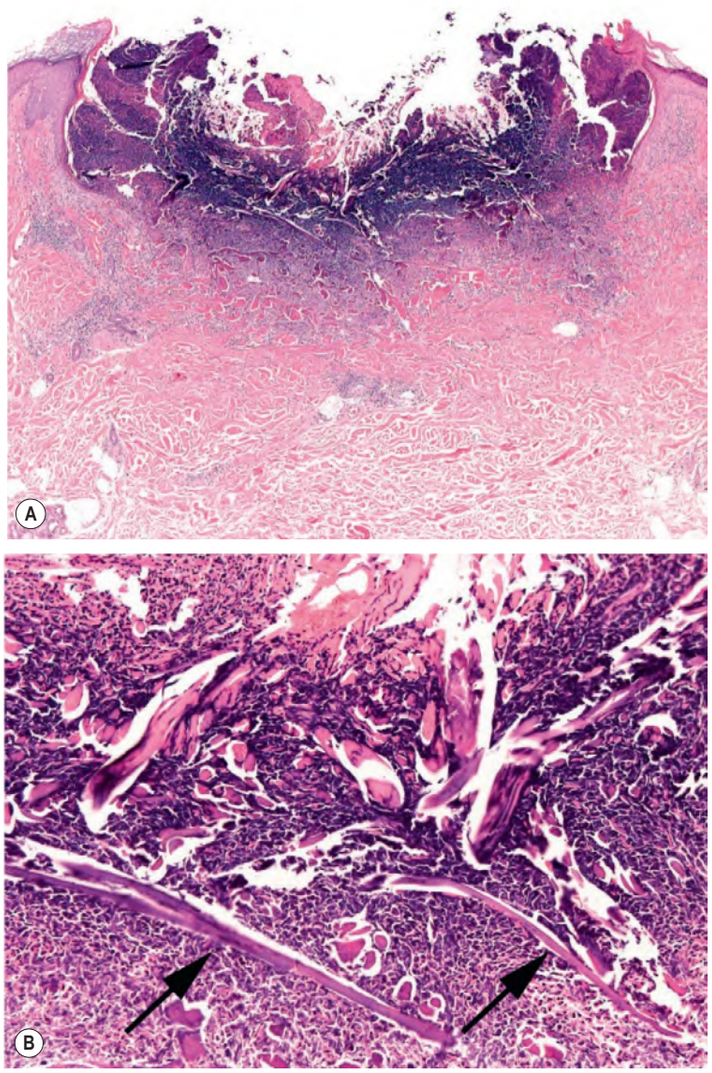

Fig. 96.9 Acquired perforating dermatosis (acquired reactive perforating collagenosis). A Scanning view of a crusted keratotic plug in a patient whose biopsy showed perforating collagen fibers. **B** Higher magnification demonstrating collagen fibers (arrows) extending into the crusted plug. *Courtesy Lorenzo Cerroni, MD.*

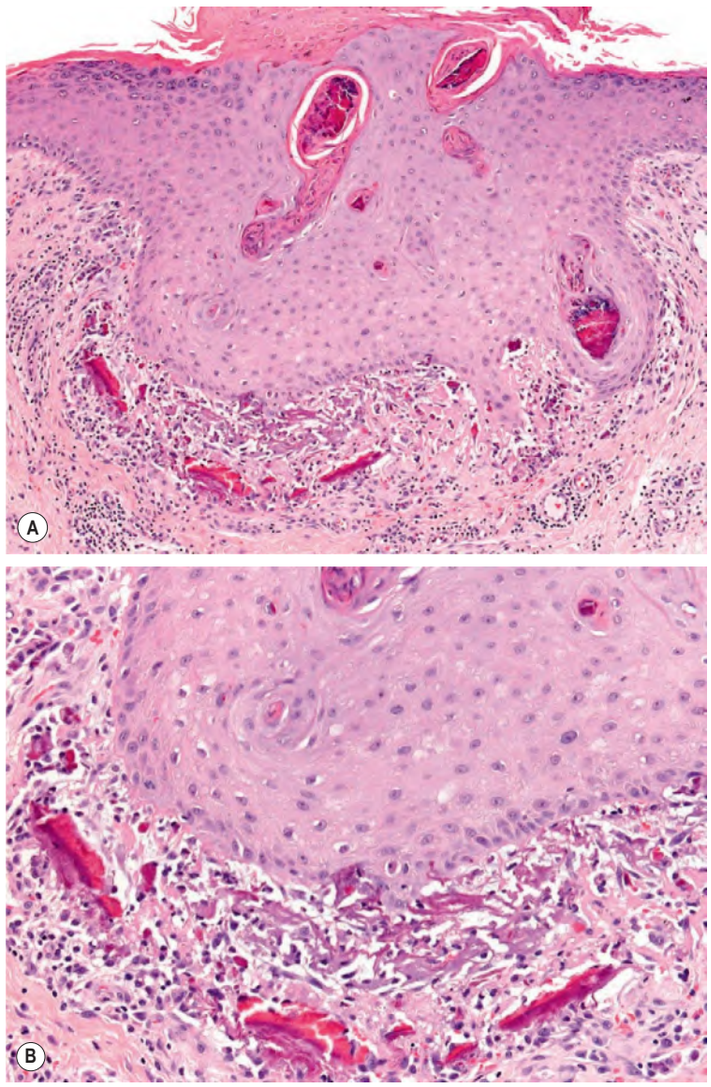

Fig. 96.11 Elastosis perforans serpiginosa. A Hyperplastic epidermis with transepidermal elimination of dermal elastic fibers via channels. Note the surface scale-crust. **B** Characteristic brightly eosinophilic elastic fibers within the superficial dermis. *Courtesy Lorenzo Cerroni, MD.*

Downloaded for Anonymous User (n/a) at Egyptian Knowledge Bank from ClinicalKey.com by Elsevier on March 10, 2024. For personal use only. No other uses without permission. Copyright ©2024. Elsevier Inc. All rights reserved.

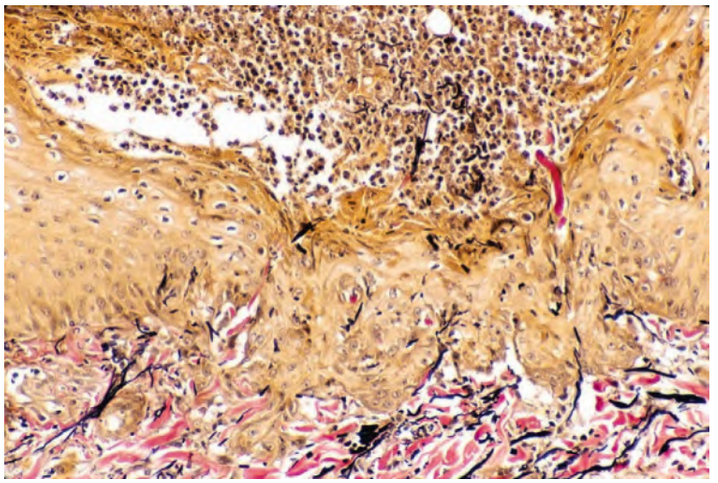

Fig. 96.12 Acquired perforating dermatosis. Transepidermal elimination of both collagen (red) and elastic fibers (black) into a crust with many neutrophils is seen (Verhoeff–van Gieson stain).

DIFFERENTIAL DIAGNOSIS OF PERFORATING DISEASES
Reactive perforating collagenosis and acquired perforating dermatosis
Excoriations from a variety of causes (prurigo simplex)
Prurigo nodularis
Folliculitis
Arthropod bites
Perforation of exogenous foreign material
Perforation of endogenous substances
Multiple keratoacanthomas
Verrucous lupus erythematosus or lichen planus
If Koebner phenomenon: psoriasis, lichen planus, verrucae (autoinoculation)
Elastosis perforans serpiginosa (resembles other annular diseases; see Ch. 19)
Granuloma annulare] Common annular diseases
Tinea
Sarcoidosis
Annular elastolytic giant cell granuloma (actinic granuloma)
Perforating pseudoxanthoma elasticum
Porokeratosis
Discoid lupus erythematosus

Table 96.3 Differential diagnosis of perforating diseases.

that intraepidermal elastic fibers can also be found in other disorders characterized by a hyperplastic epidermis (see below). In RPC, the dermal connective tissue adjacent to the plug appears unremarkable, while in EPS, an increased amount of brightly eosinophilic elastic tissue is often present in the superficial dermis (Fig. 96.11B). The Verhoeff–van Gieson stain is most helpful, because collagen fibers appear red and elastic fibers appear black (Fig. 96.12). However, in EPS, the elastic fibers higher up in the epidermis may lose their ability to stain black. In penicillamine-induced EPS, characteristic "lumpy-bumpy" elastic fibers with lateral buds resembling a "bramble bush" are seen in both lesional and non-lesional skin.

Biopsy findings in acquired perforating dermatosis vary according to the stage of evolution of the lesion. The histology may be identical to childhood RPC or EPS, or to perforating folliculitis. In other cases, it may be less specific, with amorphous degenerated material within the perforations. This material often cannot be clearly identified as collagen or elastic fibers, but sometimes both are present (see Fig. 96.12)[2]. A Japanese consensus group recently proposed classification criteria for perforating disorders based on histologic and clinical findings[21].

DIFFERENTIAL DIAGNOSIS

The differential diagnosis includes other disorders characterized by papules or nodules with central keratotic plugs or crusts, in particular prurigo simplex and prurigo nodularis (Table 96.3). Some authors, including the late A.B. Ackerman, have considered RPC to be a variant of excoriated prurigo. When the Koebner phenomenon occurs, other disorders that can also arise in a linear pattern should be considered, e.g. psoriasis, lichen planus. EPS may be confused with other disorders that are annular or serpiginous (see Ch. 19), but usually the individual keratotic plugs within the ring are distinctive. Histologically, elastic fibers may also be observed within the hyperplastic epidermis of healing wounds, keratoacanthomas, and occasionally hypertrophic lupus erythematosus and lichen simplex chronicus[22].

Since many patients with acquired perforating dermatosis have coexisting folliculitis and prurigo nodularis, there may be several different types of lesions at different stages of development and histologic findings in a single biopsy specimen may not be representative of the entire process.

Fig. 96.13 provides an algorithm for the approach to the patient with a primary perforating disorder.

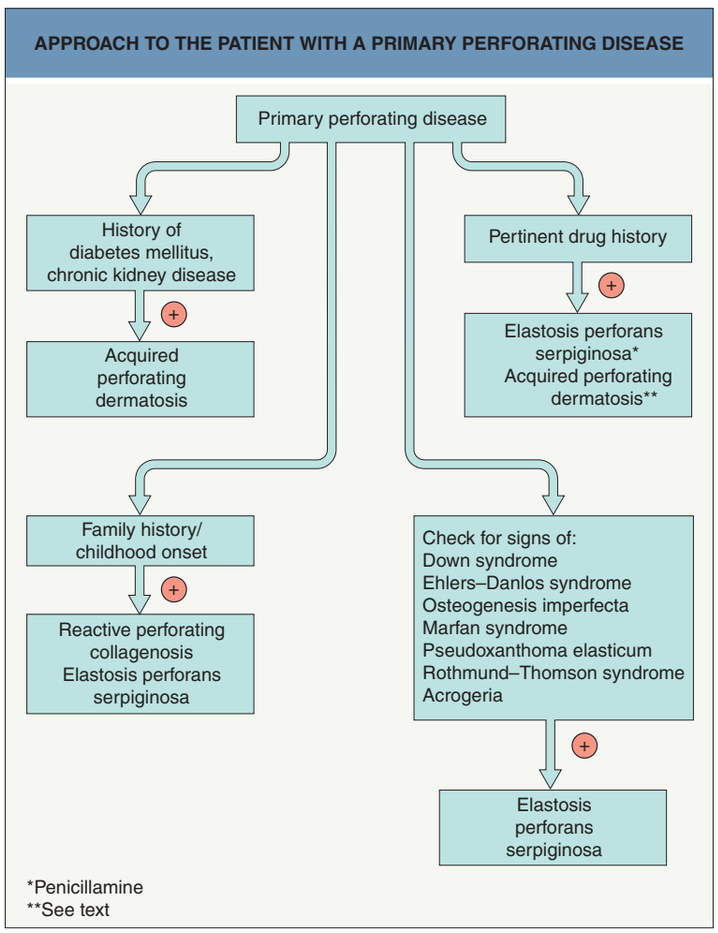

Fig. 96.13 Approach to the patient with a primary perforating disease.

TREATMENT

Table 96.4 summarizes the various treatments that have been reported, most of which are anecdotal or based upon small case series[23–29]. Well-designed, placebo-controlled studies of therapeutic interventions are needed. The inherited forms of RPC and EPS generally remain mild and localized. Sometimes local measures may be successful, but a number of authors have declared treatment to be largely ineffective. The patient with mild RPC may be counseled to simply avoid trauma and wait for lesions to resolve spontaneously.

Downloaded for Anonymous User (n/a) at Egyptian Knowledge Bank from ClinicalKey.com by Elsevier on March 10, 2024. For personal use only. No other uses without permission. Copyright ©2024. Elsevier Inc. All rights reserved.

TREATMENT OF PERFORATING DISEASES
Address contributing factors
If end-stage chronic kidney disease, transplantation may lead to improvement
Discontinue culprit medication, if possible
Topical
Retinoids (e.g. tretinoin, tazarotene)[23] (3)
Corticosteroids (3)
Menthol (3)
Salicylic acid (3)
Sulfur (3)
Benzoyl peroxide (3)
Emollients (3)
Imiquimod (3)
Cantharidin (3)
Systemic
Antihistamines (e.g. doxepin) (3)*
Corticosteroids (intralesional, intramuscular, oral) (2)
Retinoids (vitamin A, acitretin, isotretinoin) (2)
Antibiotics (e.g. doxycycline, clindamycin, erythromycin, rifampin)[24,25] (3)
Dupilumab[26] (3)
Colchicine (3)
Methotrexate (3)
Charcoal (3)
Allopurinol (3)
Other
Avoid trauma and scratching (wearing gloves, trimming fingernails, behavior modification, transcutaneous nerve stimulator) (3)
Cellophane-tape stripping (for EPS) (3)
Phototherapy (broadband or narrowband UVB > UVA1, PUVA)[27,28] (2)
Cryotherapy[29] (3)
Photodynamic therapy (3)
Electrosurgical destruction (3)
Laser ablation (e.g. CO_2, Er:YAG, excimer, pulsed dye) (3)
Excision of larger bothersome lesions (3)
*See Ch. 6 for other anti-pruritic medications.

Table 96.4 Treatment of perforating diseases. Key to evidence-based support: (1) prospective controlled trial; (2) retrospective study or large case series; (3) small case series or individual case reports. EPS, elastosis perforans serpiginosa.

EPS may be treated with local cryotherapy, tangential excision, electrosurgical destruction, laser therapy (e.g. pulsed dye, Er:YAG), or cellophane tape stripping. However, aggressive treatment is more likely to result in scarring. As with RPC, spontaneous resolution of lesions makes it difficult to evaluate therapies.

Treatment of generalized acquired perforating dermatosis or extensive perforating folliculitis is often difficult. Sedating antihistamines and other typical "anti-itch" treatments (see Ch. 6) are often prescribed in an attempt to reduce the associated pruritus. Phototherapy (usually broadband or narrowband UVB) is a particularly good choice for patients with chronic kidney disease, since it often relieves coexisting pruritus. Other therapies that are sometimes helpful include intralesional corticosteroids and oral[15] or topical retinoids. Dupilumab was reported to significantly improve acquired RPC in the setting of adult atopic dermatitis[26]. Anecdotally, some patients have attributed rapid improvement to a change in the type of dialysis tubing or equipment employed, or even an alteration in the methods used during the actual dialysis procedure (personal observation). Occasional dialysis patients with acquired perforating dermatosis have been cured after renal transplantation[13].

Additional figures available in our eBook (see inside front cover for access code).

REFERENCES

1. Flannigan SA, Tucker SB, Rapini RP. Recurrent hyperkeratotic papules from superficial trauma: reactive perforating collagenosis (RPC). *Arch Dermatol*. 1985;121:1554–1555, 1557–1558.
2. Rapini RP, Hebert AA, Drucker CR, et al. Acquired perforating dermatosis. Evidence of combined transepidermal elimination of both collagen and elastic fibers. *Arch Dermatol*. 1989;125:1074–1078.
3. Rubio FA, Herranz P, Robayna G, et al. Perforating folliculitis: report of a case in an HIV-infected man. *J Am Acad Dermatol*. 1999;40:300–302.
4. Karpouzis A, Giatromanolaki A, Sivridis E, Kouskoukis C. Acquired reactive perforating collagenosis: current status. *J Dermatol*. 2010;37:585–592.
5. Cordova KB, Oberg TJ, Malik M, Robinson-Bostom L. Dermatologic conditions seen in end-stage renal disease. *Semin Dial*. 2009;22:45–55.
6. Fujimoto N, Akagi A, Tajima S, et al. Expression of the 67-kDa elastin receptor in perforating skin disorders. *Br J Dermatol*. 2002;146:74–79.
7. Fujimoto E, Kobayashi T, Fujimoto N, et al. AGE-modified collagens I and III induce keratinocyte terminal differentiation through AGE receptor CD36: epidermal-dermal interaction in acquired perforating dermatoses. *J Invest Dermatol*. 2010;130:405–414.
8. Bellinato F, Maurelli M, Gisondi P, Girolomoni G. Acquired perforating dermatoses show increased levels of cutaneous advanced glycation end-products. *Clin Exp Dermatol*. 2022;47:80–85.
9. Bilezikci B, Seckin D, Demirhan B. Acquired perforating dermatosis in patients with chronic renal failure: a possible role for fibronectin. *J Eur Acad Dermatol Venereol*. 2003;17:230–232.
10. Herzinger T, Schirren CG, Sander CA, et al. Reactive perforating collagenosis – transepidermal elimination of type IV collagen. *Clin Exp Dermatol*. 1996;21:279–282.
11. Gambichler T, Birkner L, Stucker M, et al. Up-regulation of transforming growth factor-beta3 and extracellular matrix proteins in acquired reactive perforating collagenosis. *J Am Acad Dermatol*. 2009;60:463–469.
12. Zelger B, Hintner H, Aubock J, et al. Acquired perforating dermatosis. Transepidermal elimination of DNA material and possible role of leukocytes in pathogenesis. *Arch Dermatol*. 1991;127:695–700.
13. Saldanha LF, Gonick HC, Rodriguez HJ, et al. Silicon-related syndrome in dialysis patients. *Nephron*. 1997;77:48–56.
14. Ramesh V, Sood N, Kubba A, et al. Familial reactive perforating collagenosis: a clinical, histopathological study of 10 cases. *J Eur Acad Dermatol Venereol*. 2007;21:766–770.
15. Delacretaz J, Gattlen JM. Transepidermal elimination of traumatically altered collagen. Report of three cases and consideration on the relationship between 'collagenome perforant verruciformé' and reactive perforating collagenosis. *Dermatologica*. 1976;152:65–66.
16. Vearrier D, Buka RL, Roberts B, et al. What is the standard of care in the evaluation of elastosis perforans serpiginosa? A survey of pediatric dermatologists. *Pediatr Dermatol*. 2006;23:219–224.
17. Hellriegel S, Bertsch HP, Emmert S, et al. Elastosis perforans serpiginosa: a case of penicillamine-induced degenerative dermatosis. *JAMA Dermatol*. 2014;150:785–787.
18. Weng CH, Hu CC, Ueng SH, et al. Predictors of acquired perforating dermatosis in uremic patients on hemodialysis: a case-control study. *ScientificWorldJournal*. 2012;2012:158075.
19. Akoglu G, Emre S, Sungu N, et al. Clinicopathological features of 25 patients with acquired perforating dermatosis. *Eur J Dermatol*. 2013;23:864–871.
20. Lopes LC, Lobo L, Bajanca R. Perforating calcific elastosis. *J Eur Acad Dermatol Venereol*. 2003;17:206–207.
21. Kawakami T, Akiyama M, Ishida-Yamamoto A, et al. Clinical practice guide for the treatment of perforating dermatosis. *J Dermatol*. 2020;47:1374–1382.
22. Shah K, Kazlouskaya V, Lal K, et al. Perforating elastic fibers ('elastic fiber trapping') in the differentiation of keratoacanthoma, conventional squamous cell carcinoma and pseudocarcinomatous epithelial hyperplasia. *J Cutan Pathol*. 2014;41:108–112.
23. Outland JD, Brown TS, Callen JP. Tazarotene is an effective therapy for elastosis perforans serpiginosa. *Arch Dermatol*. 2002;138:169–171.
24. Gonul M, Cakmak SK, Gul U, et al. Two cases of acquired perforating dermatosis treated with doxycycline therapy. *Int J Dermatol*. 2006;45:1461–1463.
25. Kasiakou SK, Peppas G, Kapaskelis AM, Falagas ME. Regression of skin lesions of Kyrle's disease with clindamycin: implications for an infectious component in the etiology of the disease. *J Infect*. 2005;50:412–416.
26. Ying Y, Shuang C, Zhen-Ying Z. Dupilumab may be an alternative option in the treatment of acquired reactive perforating collagenosis combined with AD. *Immun Inflamm Dis*. 2022;10:e574.
27. Sehgal VN, Verma P, Battacharya SN, et al. Familial reactive perforating collagenosis in a child: response to narrow-band UVB. *Pediatr Dermatol*. 2013;30:762–764.
28. Mii S, Yotsu R, Hayashi R, et al. Acquired perforating collagenosis successfully treated with narrow-band ultraviolet B. *Acta Derm Venereol*. 2009;89:530–531.
29. Kalkan G, Sahin M, Vahaboglu G, et al. A case of elastosis perforans serpiginosa treatment with cryotherapy. *Int J Dermatol*. 2012;51:1487–1490.

Downloaded for Anonymous User (n/a) at Egyptian Knowledge Bank from ClinicalKey.com by Elsevier on March 10, 2024. For personal use only. No other uses without permission. Copyright ©2024. Elsevier Inc. All rights reserved.

eFig. 96.1 Reactive perforating collagenosis. This keratotic papule on the upper extremity followed minor trauma in a healthy man who had developed similar papules since childhood.

eFig. 96.2 Acquired perforating dermatosis in a patient with diabetes mellitus. *Courtesy Lorenzo Cerroni, MD.*

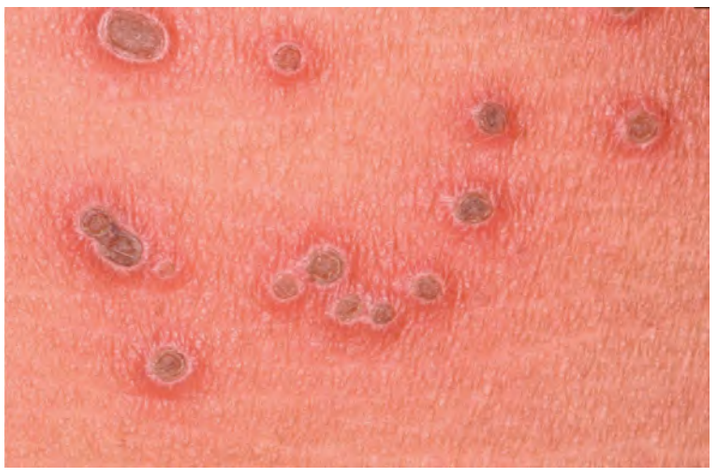

eFig. 96.3 Acquired perforating dermatosis. Erythematous papules with central keratotic cores in a patient with chronic kidney disease. Sometimes the latter are dislodged by the patient. *Courtesy Lorenzo Cerroni, MD.*

eFig. 96.4 Acquired perforating dermatosis. Keratotic papules on the arm of a diabetic woman on hemodialysis. Note the central keratotic core which is sometimes dislodged by the patient.

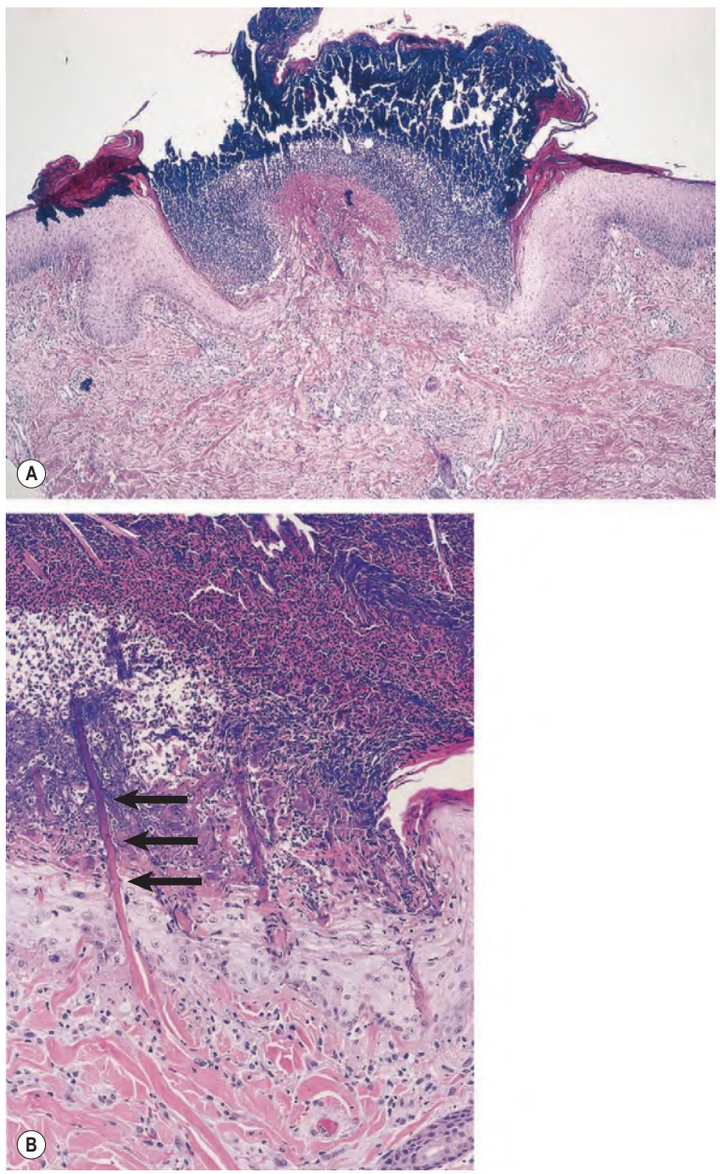

eFig. 96.5 Acquired perforating dermatosis (acquired reactive perforating collagenosis). A Scanning view of a crusted keratotic plug in a patient whose biopsy showed perforating collagen fibers. **B** Higher magnification demonstrating collagen fibers extending through the epidermis (arrows) into the crusted plug.

Downloaded for Anonymous User (n/a) at Egyptian Knowledge Bank from ClinicalKey.com by Elsevier on March 10, 2024. For personal use only. No other uses without permission. Copyright ©2024. Elsevier Inc. All rights reserved.

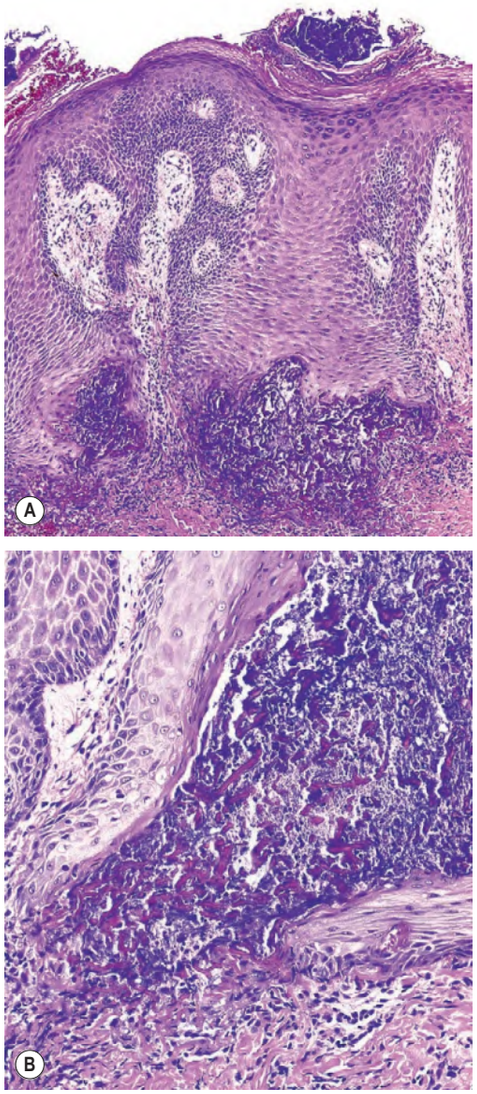

eFig. 96.6 Elastosis perforans serpiginosa. **A** Hyperplastic epidermis clutches the increased dermal elastic fibers like a claw. **B** Transepidermal elimination of neutrophils and elastic fibers from the dermis through a channel in the epidermis.

Downloaded for Anonymous User (n/a) at Egyptian Knowledge Bank from ClinicalKey.com by Elsevier on March 10, 2024. For personal use only. No other uses without permission. Copyright ©2024. Elsevier Inc. All rights reserved.